



# A phase 2, open-label, multi-center study to evaluate the efficacy and safety of $^{99m}\text{Tc}$ -TRODAT-1 SPECT to detect Parkinson's disease

Yu Sun<sup>1</sup> · Congjin Liu<sup>1</sup> · Zhengping Chen<sup>2</sup> · Biao Li<sup>3</sup> · Zhongwei Lv<sup>4</sup> · Jian Wang<sup>5</sup> · Jingjing Lou<sup>6</sup> · Jie Tang<sup>2</sup> · Yuankai Wang<sup>1</sup> · Guangming Zhang<sup>1</sup> · Xingdang Liu<sup>1</sup>

Received: 2 July 2019 / Accepted: 7 October 2019 / Published online: 23 October 2019  
© The Japanese Society of Nuclear Medicine 2019

## Abstract

**Objectives** To assess the efficacy and safety of  $^{99m}\text{Tc}$ -TRODAT-1 SPECT in diagnosing Parkinson's disease (PD).

**Methods**  $^{99m}\text{Tc}$ -TRODAT-1 SPECT imaging was performed in 34 healthy controls and 96 PD patients 2.5 h later after injection. The striatal image was evaluated visually and semi-quantitatively. Sensitivity and specificity of  $^{99m}\text{Tc}$ -TRODAT-1 SPECT were analyzed according to Hoehn and Yahr scale (HYS). Based on HYS, the PD patients were divided into mild (HYS 1–2) and moderate (HYS 3–5) groups. The uptake ratios of striatum (ST) and cerebellum (CB) in contralateral, ipsilateral and bilateral striatum in different groups were calculated and analyzed. The safety was assessed.

**Results** The sensitivity and specificity of  $^{99m}\text{Tc}$ -TRODAT-1 SPECT to discriminate PD patients from healthy subjects were 98.96% and 94.12% and it has perfect agreement with HYS ( $\kappa=0.94$ ,  $p<0.001$ ). The sensitivity to diagnose mild and moderate PD was 43.42% and 95% separately. The uptake ratio in PD patients was significantly lower than that in healthy controls ( $1.37 \pm 0.13$  vs  $1.68 \pm 0.18$ ,  $p<0.001$ ). And the uptake ratio in contralateral side was markedly reduced in unilateral PD patients as compared with the ipsilateral side ( $1.50 \pm 0.20$  vs  $1.46 \pm 0.21$ ,  $p<0.001$ ). The striatal uptakes in affected striatum and bilateral striatum were reduced with increasing disease severity between healthy control versus mild stage versus moderate stage in the affected striatum and bilateral striatum in PD patients. No serious adverse events or death was observed after injecting  $^{99m}\text{Tc}$ -TRODAT-1.

**Conclusion** We demonstrated that  $^{99m}\text{Tc}$ -TRODAT-1 was a safety radiotracer which can be used in clinic to diagnose PD using SPECT.

**Keywords** Phase 2 clinical trial ·  $^{99m}\text{Tc}$ -TRODAT-1 · Dopamine transporter · Diagnostic efficacy · Parkinson's disease

Yu Sun and Congjin Liu have contributed equally to this work.

✉ Jingjing Lou  
1436150464@qq.com

✉ Xingdang Liu  
xingdliu@fudan.edu.cn

<sup>1</sup> Department of Nuclear Medicine, Huashan Hospital, Fudan University, No. 12 Wulumuqi Middle Road, Jing'an District, Shanghai 200040, China

<sup>2</sup> Key Laboratory of Nuclear Medicine, Ministry of Health, Jiangsu Key Laboratory of Molecular Nuclear Medicine, No. 20 Qianrong Road, Binhu District, Wuxi 214063, Jiangsu, China

<sup>3</sup> Department of Nuclear Medicine, Ruijin Hospital, Shanghai Jiaotong University, No. 197, Ruijin Er Road, Shanghai 200025, China

<sup>4</sup> Department of Nuclear Medicine, Shanghai Tenth People's Hospital, Tongji University School of Medicine, 301 Yangchang Middle Road, Jing'an District, Shanghai 200072, China

<sup>5</sup> Department of Neurology and National Clinical Research Center for Aging and Medicine, Huashan Hospital, Fudan University, No. 12 Wulumuqi Middle Road, Jing'an District, Shanghai 200040, China

<sup>6</sup> Universal Medical Imaging Diagnostic Center, No. 406 Guilin Road, Xuhui District, Shanghai 200233, China

## Introduction

Parkinson's disease (PD) is a progressive neurodegenerative disorder characterized by motor and nonmotor symptoms. Its pathological feature is the degeneration of dopaminergic neurons in the substantia nigra. The current diagnosis of PD is mainly based on the clinical symptoms, such as resting tremor, rigidity, slowness of movements, postural instability, dementia and dysautonomia [1]. But there are no clinical symptoms in the early stage of PD until 50% of nigral neurons and 80% of striatal dopamine are lost [2]. So, the detection methods relying on the decreased dopaminergic neurons were developed widely to diagnose PD.

Dopamine transporter (DAT), located on the presynaptic dopaminergic nerve terminal, maintains dopamine homeostasis via reuptake dopamine into the nerve terminal. The loss of dopaminergic neurons leads to the reduction of DAT [3]. Many radiotracers which can bind specifically to DAT were developed to diagnose PD, including SPECT tracers such as  $^{99m}\text{Tc}$ -TRODAT-1,  $^{123}\text{I}$ -beta-CIT,  $^{123}\text{I}$  FP-CIT, and PET tracers such as  $^{11}\text{C}$ -CFT,  $^{18}\text{F}$ -CFT,  $^{18}\text{F}$ -FP-CIT [4, 5]. Among them,  $^{123}\text{I}$ ,  $^{11}\text{C}$  and  $^{18}\text{F}$  are produced from cyclotron, which is of high cost and limits its widespread use in clinic [6]. By contrast,  $^{99m}\text{Tc}$  can be eluted from  $^{99}\text{Mo}/^{99m}\text{Tc}$  generators which is of low cost and can easily transport over long distances.  $^{99m}\text{Tc}$ -TRODAT-1, developed by Kung et al., has shown high affinity and specificity for DAT [7–9]. A series of studies using  $^{99m}\text{Tc}$ -TRODAT-1 SPECT were performed to detect the dopaminergic function in both animal and human, especially with PD [10–13]. Many studies have indicated that  $^{99m}\text{Tc}$ -TRODAT-1 can not only be used to diagnose the late onset PD but also the early PD [13–15].  $^{99m}\text{Tc}$ -TRODAT-1 will be a good and specifically radiotracer to diagnose PD in clinic. We previously carried out the phase I clinical study of  $^{99m}\text{Tc}$ -TRODAT-1 in healthy adults to investigate its safety, pharmacokinetics, biodistribution, and injection doses which showed that  $^{99m}\text{Tc}$ -TRODAT-1 is safety to be used in human and can show the status of dopaminergic neurons specifically and clearly. Now, in this study, we perform phase 2 clinical trial to investigate its diagnostic efficacy and safety in PD patients.

## Materials and methods

This study was approved by China Food and Drug Administration (Approval number: 2007L03822) and the ethics committee of Huashan Hospital Affiliated to Fudan University. All procedures performed in this study were in

accordance with the guidelines of “Good Clinical Practice (GCP)” and with the principles of the 1964 Declaration of Helsinki and its later amendments. Informed consent was obtained from all participants included in the study.

## Subjects

Written informed consent was signed by all participants who were informed of all aspects of the study and agreed to participate in this trial voluntarily. After medical history, physical examination, laboratory tests and other tests, 34 healthy controls in non-PD group (NPD) and 96 PD patients in PD group (PD) in three medical centers were enrolled in this study based on inclusion and exclusion criteria as followed from January 2011 to December 2012.

Inclusion criteria were: aged 40–75 years; the range of the body mass index (BMI) was 19–25; no drugs that may affect the efficacy of the trial was used within 48 h prior to the trial; no obvious structural abnormality in basal ganglia detected by MRI; the participants understood the purpose and process of this study and signed the informed consent form voluntarily. PD patients are diagnosed with Parkinson's disease according to the United Kingdom (UK) Brain Bank criteria. For healthy controls, they have no neurological signs through neurological examination.

Exclusion criteria were: women in gestational and lactational period; mental or physical disability; inadequate hepatic or renal functions; past and present history of drugs or alcohol abuse; history of hypersensitivity to drugs or food; received other drug clinical trial within 3 months; received any other radionuclide imaging within 14 days.

## Radiopharmaceutical

$^{99m}\text{Tc}$ -TRODAT-1 was synthesized as previously described [16]. 740–1110MBq (20–30mCi)  $\text{Na}^{99m}\text{TcO}_4$  was injected into the bottle of TRODAT-1 (50ug/bottle) which was supplied by Jiangsu Key Laboratory of Molecular Nuclear Medicine and shaking gently to make the freeze-dried TRODAT-1 dissolve completely. The pH was adjusted to 6–7, allowed it to stand for 5minutes and then heated in boiling water bath for 30 min. After cooling, the reaction complex was extracted from the aqueous reaction medium with ethyl acetate and passed through a small amount of  $\text{Na}_2\text{SO}_4$ . The ethyl acetate was removed under a flow of nitrogen. The residue was dissolved in EtOH and saline and then sterilized by a filter. After removing the first receiver vial, the  $^{99m}\text{Tc}$ -TRODAT-1 was eluted with 50/50 ethanol/water and diluted to the required concentration with sterile saline in a sterile receiver vial. The radiochemical purity of  $^{99m}\text{Tc}$ -TRODAT-1 was evaluated by high-performance liquid chromatography (HPLC) which was all greater than 90% for each preparation.

In phase 1 clinical trial, we found that when the injection dose was about 740MBq (20mCi), the striatal images were better than the injection dose of 370MBq (10mCi) and the patients received less radioactivity than the injection dose of 1110MBq (30mCi). So, in this study, the injection dose was about 740MBq (20mCi).

### Striatal imaging analysis

The brain SPECT was performed at 2.5 h after injection using high-resolution fan beam collimators of Siemens NME.CAM Gantry Dual-Head Ex. Base (Siemens, Germany). Brain images were acquired in a 128 × 128 matrix through 360° rotation (180° for each head). The energy was 140 keV. Images were reconstructed using ramp-Butterworth filter. The SPECT which has dual-head camera, scanning parameter and reconstruction method in different centers were all the same. The striatum image evaluated visually by professional doctors was classified as normal and abnormal, or normal, mild and moderate. According to the Hoehn and Yahr scale (HYS), the PD patients were classified as mild (stages 1 and 2), moderate (stage 3) and severe (stages 4 and 5). Because there were just 4 severe patients, so the severe patients were analyzed as moderate patients. The sensitivity and specificity of <sup>99m</sup>Tc-TRODAT-1 SPECT to diagnose PD were analyzed compared with HYS.

Regions of interest (ROI) of bilateral striatum was drawn on the slice with the highest activity by 2 independent readers blind to each other. The ROI of cerebellum was also drawn in the same way and served as background areas. The ratio of ST and CB was calculated as the radioactivity uptake value of DAT in the striatum.

### Safety assessment

Within 14 days before injection and 24 h after injection, the physical examination, vital signs, hematological test, biochemical test and urinary test were all detected. The 12-lead electrocardiogram was also done within 14 days before injection. Before injection and 2 h after injection at study day, the vital signs were checked again.

### Statistical analysis

Data were shown as mean ± SD. *T* test was used to analyze the quantitative data including the characteristic data of subjects and the radioactive uptake ratio in striatum. The differences in gender and dominant hand between NPD and PD group were analyzed by Chi-square test and Fisher's exact test separately. Kappa test was used to investigate the degree of agreement between <sup>99m</sup>Tc-TRODAT-1 SPECT and HYS.

## Results

### The characteristics of the subjects

The average age has no significant difference between the healthy controls and PD patients ( $57.62 \pm 6.18$  years vs  $59.68 \pm 7.72$  years,  $p=0.162$ ). The injection doses in these two groups were almost the same,  $775.89 \pm 46.62$  MBq ( $20.97 \pm 1.26$  mCi) in NPD group and  $769.23 \pm 42.92$  MBq ( $20.79 \pm 1.16$  mCi) in PD group ( $p=0.429$ ). In an analysis of the gender, we found that the ratio of male to female in PD group was more than that in NPD group (1.67 vs 0.70,  $p=0.031$ , Table 1). For other characteristics including the dominant hand, height weight temperature and vital signs, there were no significant differences between the two groups (Table 1).

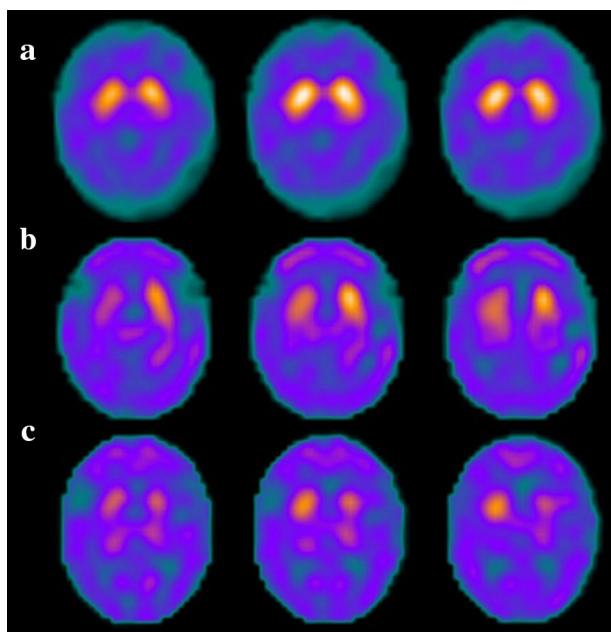
### The diagnostic efficacy of <sup>99m</sup>Tc-TRODAT-1 SPECT

<sup>99m</sup>Tc-TRODAT-1 SPECT brain image showed that <sup>99m</sup>Tc-TRODAT-1 can bind specially to the dopaminergic neurons in the striatum which have high radioactive uptake in bilateral striatum and little uptake in other places in the brain (Fig. 1a). In healthy controls, the radioactive uptake in left and right striatum was both high and the structures of them were both intact (Fig. 1a). But in PD patients, the affected striatum or bilateral striatum has marked decreased radioactive uptake, especially in the putamen (Fig. 1b, c). The PD patients could be easily distinguished visually from the healthy controls through the SPECT images.

**Table 1** Characteristics of subjects in NPD and PD groups

Parameter	NPD group	PD group	<i>p</i> value
Number	34	96	
Injection dose (MBq)	$775.89 \pm 46.62$	$769.23 \pm 42.92$	0.429
Age (year)	$57.62 \pm 6.18$	$59.68 \pm 7.72$	0.162
Gender (M/F)	14/20 (0.70)	60/36 (1.67)	0.031
Dominant hand (L/R)	0/34 (0%/100%)	2/94 (2.1%/97.9%)	1.000
Height (cm)	$163.94 \pm 7.21$	$165.84 \pm 8.37$	0.240
Weight (kg)	$61.81 \pm 7.64$	$62.37 \pm 8.78$	0.741
Temperature (°C)	$36.59 \pm 0.27$	$36.59 \pm 0.26$	0.933
Pulse rate (bpm)	$75.26 \pm 10.02$	$76.80 \pm 11.60$	0.493
Respiratory rate (bpm)	$17.41 \pm 2.06$	$17.14 \pm 2.39$	0.550
Systolic pressure (mmHg)	$129.53 \pm 11.91$	$128.05 \pm 12.33$	0.546
Diastolic pressure (mmHg)	$80.35 \pm 8.40$	$80.95 \pm 7.79$	0.708

NPD non-Parkinson's disease, PD Parkinson's disease, M male, F female, L left hand, R right hand

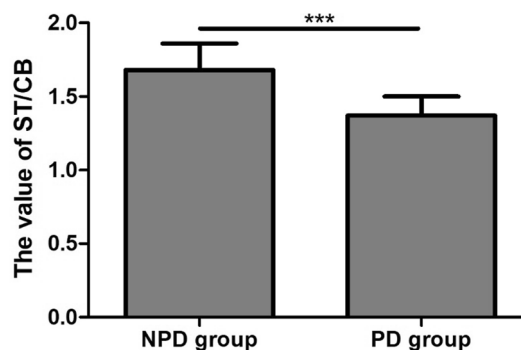


**Fig. 1** The representative striatum images of  $^{99m}\text{Tc}$ -TRODAT-1 SPECT in healthy control and PD patients. **a** The uptake values in bilateral striatum were almost the same in the healthy control; **b** the radioactivity in the contralateral striatum was lower than that in the ipsilateral striatum in PD patients; **c** the radioactivity in both striatum was decreased in PD patients

Table 2 shows the sensitivity and specificity of  $^{99m}\text{Tc}$ -TRODAT-1 SPECT to diagnose PD based on the HYS. It has 98.96% sensitivity and 94.12% specificity to discriminate PD patients from healthy subjects. The Kappa test showed that the diagnosis efficacy of  $^{99m}\text{Tc}$ -TRODAT-1 SPECT was almost in perfect agreement with HYS when discriminating the abnormal from the normal subjects (Kappa coefficient = 0.94,  $p < 0.001$ ). Based on HYS, the PD patients were divided into mild and moderate PD whose sensitivity was 43.42% and 94.12% respectively.

### The radioactive uptake ratio in the striatum

The value of ST/CB in the striatum in PD group was  $1.37 \pm 0.13$  which was significantly lower than that in the NPD group ( $1.68 \pm 0.18$ ,  $p < 0.001$ , Fig. 2). In the unilateral PD patients, though the difference value of ST/CB between



**Fig. 2** The values of ST/CB in the striatum in NPD and PD group. The NPD group contained the bilateral striatum. The PD group included the affected striatum in the unilateral PD patients and the bilateral striatum in the bilateral PD patients. \*\*\* $p < 0.001$

the ipsilateral side (striatum located at the side with dominant symptoms) and contralateral side (striatum located at the opposite the side with dominant symptoms) was just  $0.04 \pm 0.08$ , there were significant differences between them ( $1.50 \pm 0.20$  vs  $1.46 \pm 0.21$ ,  $p < 0.001$ ). What is more, the uptake value in the ipsilateral side was markedly reduced compared to that in the bilateral striatum in healthy controls ( $1.50 \pm 0.20$  vs  $1.68 \pm 0.18$ ,  $p < 0.001$ ). PD patients were divided into mild and moderate scale groups and its uptake values in striatum were analyzed. The results showed that the uptakes in the ipsilateral, affected and bilateral side in the mild and moderate scales were all markedly lower than those in the normal scales (Fig. 3, the radio uptake ratio in the normal scales refers to that in the bilateral striatum in healthy controls.). In the affected and bilateral side, the uptake value in the mild scale was significantly higher than that in the moderate scale (the affected side:  $1.39 \pm 0.13$  vs  $1.30 \pm 0.13$ ,  $p = 0.02$ ; the bilateral side:  $1.41 \pm 0.13$  vs  $1.30 \pm 0.15$ ,  $p = 0.01$ , Fig. 3). But there was no obvious difference between mild and moderate scale in the ipsilateral side ( $1.44 \pm 0.15$  vs  $1.33 \pm 0.20$ ,  $p = 0.05$ , Fig. 3).

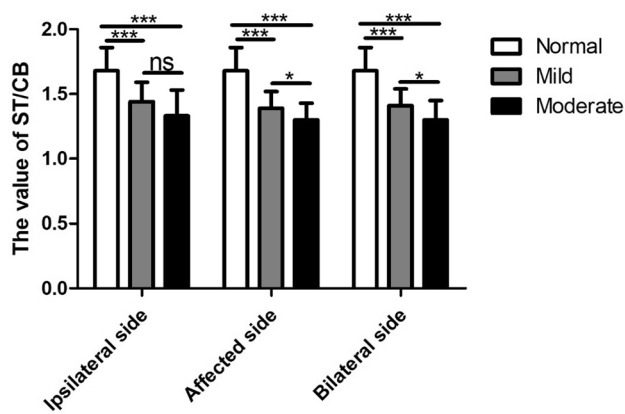
### Safety assessment

In the present study, no serious adverse events or death were observed. Adverse reactions that may be caused by

**Table 2** The sensitivity and specificity of  $^{99m}\text{Tc}$ -TRODAT-1 SPECT to distinguish PD patients from healthy controls

Image	H&Y Scale (No.)			Sensitivity (%)	Specificity (%)	Kappa test	
	Normal	Abnormal	Total			$\kappa$	$p$ value
Normal	32	1	33	98.96	94.12	0.94	<0.001
Abnormal	2	95	97				
Total	34	96	130				

PD Parkinson's disease, H&Y scale Hoehn and Yahr scale, No. number,  $\kappa$  Kappa coefficient



**Fig. 3** The values of ST/CB of different HYSs in different sides of striatum. The normal refers to the bilateral striatum in healthy controls. The ipsilateral side was the striatum located at the side with dominant symptoms in unilateral PD patients. The affected side included striatum located opposite the side with dominant symptoms in the unilateral PD patients and bilateral striatum in bilateral PD patients. The bilateral side was the bilateral striatum in unilateral and bilateral PD patients. \*\*\* $p < 0.001$ ; \* $p < 0.05$ ; ns no significant difference

**Table 3** The adverse reaction after injecting  $^{99m}\text{Tc}$ -TRODAT-1

No.	Group	Adverse reaction
11008	PD	Dizziness
21016	PD	Abnormal AST level: from 15 to 46 U/L Abnormal ALT level: from 11 to 68 U/L
31017	PD	Dizziness
31019	PD	Abnormal WBC level: from $5.6 \times 10^9/\text{L}$ to $2.83 \times 10^9/\text{L}$ Abnormal total protein level: from 69 to 59 g/L Abnormal albumin level: from 38 to 31 g/L

$^{99m}\text{Tc}$ -TRODAT-1 occurred in 4 cases shown in Table 3. 2 patients had dizziness after injection. One had increased AST and ALT levels and the other one had decreased white blood cell count, decreased total protein level and decreased albumin level. The reactions of these 4 patients were all mild.

## Discussion

It has been a long and arduous process of  $^{99m}\text{Tc}$ -TRODAT-1 for evaluating dopaminergic function since it was first developed by Hank F. Kung in 1997 [17]. A series of studies were performed to diagnose neurodegenerative disorders, especially Parkinson's disease [18]. Nowadays, its important roles in diagnosis PD from healthy controls and non-PD patients with Parkinsonism symptoms, and early diagnosis

of PD have been accepted [11, 13, 19–23]. But in China, still there was no  $^{99m}\text{Tc}$ -TRODAT-1 used in routine clinical detection. So, we performed series of clinical trials to investigate whether  $^{99m}\text{Tc}$ -TRODAT-1 synthesized by Jiangsu Key Laboratory of Molecular Nuclear Medicine can be used as routine clinical imaging agent for diagnosing PD.

Phase I clinical study which has been finished showed that  $^{99m}\text{Tc}$ -TRODAT-1 was a safe radiotracer and could bind DAT specifically and clearly in striatum in healthy subjects. In this present study, the striatum image was also clearly shown in both healthy controls and PD patients. The radio uptake ratio in PD patients was obviously decreased in striatum compared with control individuals, which are in line with the findings of previous studies [24–26]. The reduction in the putamen was more severe than that in the caudate nucleus in PD, which was the same as the pathologic condition [27]. Many other researches also demonstrated this reduction [14, 15, 28, 29]. Not just the severity of putamen, the frequency of putamen was also much more than caudate. Payam Sasannezhad et al. [14] found that 66.67% caudate nucleuses had decreased tracer uptake while 100% putamen had decreased or absent tracer uptake. Our study showed that  $^{99m}\text{Tc}$ -TRODAT-1 SPECT had high sensitivity (98.96%) and specificity (94.12%) to distinguish PD from healthy controls through analyzing the radio uptake ratio in striatum. In Eng et al.'s study, the sensitivity of contralateral and ipsilateral ratio of striatal/occipital ((striatum counts—occipital cortex counts)/occipital cortex counts, S/O) were 98.6% and 94.4% which were similar with our study. But their specificities (both 100%) were slightly higher than those of our study. Furthermore, they also analyzed the sensitivity and specificity of contralateral and ipsilateral S/O of PD patients with H–Y stage 1 which were 100%, 100% and 92.9%, 100% [25]. While, in our study, the sensitivity to diagnose mild PD (HYS 1–2) was just 43.42%. But for moderate PD (HYS 3–5), it can reach 95%. In Edson et al. [24]'s research including 20 PD patients and 9 healthy subjects, the sensitivity to diagnose PD was 100%, but its specificity was just 89%.

In addition to analyzing the radio uptake ratio of striatum, the ratios of putamen or caudate nucleus were also used to diagnose PD. But its diagnostic accuracy was worse than that of striatum. Weng et al. [25] showed that the sensitivity and specificity of putamen/occipital cortex ratios were 100%. However, in Edson et al. [24]'s study, they were just 85% and 89%. Analyzing anterior and posterior putamen separately, the sensitivity/specificity were 66%/89% and 79%/92% [15]. For caudate nucleus, one study showed that the sensitivity/specificity were 100%/56% [24], while the other was 48%/84% [15]. Therefore, the striatum was the best region used to diagnose PD. The results of semi-quantitative analysis showed that the striatum uptake in PD patients was obviously lower than that in healthy controls, which was in line with other studies [13, 24, 30, 31]. And

the reduction in striatal uptake with increasing disease severity was found in PD patients. The uptake in HYS 3–5 was markedly lower than that in HYS 1–2. One other study showed that the differences between specific uptake ratios of controls vs stage 1, stage 1 vs 2, 1 vs 3, 1 vs 4, and 2 vs 4 were statistically significant [32]. And another study demonstrated that there were significant differences between healthy control vs stage vs 2 vs 3 [33]. We also investigated the difference between the radio uptake ratio contralateral to symptoms and the ipsilateral side which showed that the uptake of contralateral side was markedly reduced which was also confirmed in other studies [22, 28, 29, 32]. And the radio uptake ratio in ipsilateral side in unilateral PD patients was lower than that in bilateral striatum in healthy controls also shown in other studies [13, 15, 25, 32].

In our study, we found that more male was recruited than the female in PD patients. The difference of PD incidence between male and female has been confirmed in many other studies [34–37]. Men are at greater risk for PD than women. But the reasons are still not known. It may be related with the lifestyle, estrogen, Leber's hereditary optic neuropathy, gene and other factors [38–41]. Further studies are needed to be performed in the future.

There were no remarkable adverse reactions found in both healthy controls and PD patients just like the other studies [42]. But there were mild adverse reactions in four subjects. Two had dizziness who turned to normal later. But there were no other studies that reported subjects suffered from dizziness. The other two had abnormal blood tests which were normal and unchanged during the examination and after injection in other studies [42]. These adverse reactions observed in our present study may be related to  $^{99m}\text{Tc}$ -TRODAT-1 which need to be further studied. In general,  $^{99m}\text{Tc}$ -TRODAT-1 was a safety radiotracer which can be used in PD patients.

## Conclusion

This phase 2, open-label and multi-center study indicated that  $^{99m}\text{Tc}$ -TRODAT-1 was a safety radiotracer which can bind to DAT in striatum with high affinity and specificity. With high sensitivity and specificity,  $^{99m}\text{Tc}$ -TRODAT-1 SPECT can serve as a clinical detection method to diagnose PD. And it also can assist in the assessment the severity of PD.

**Funding** None.

## Compliance with ethical standards

**Conflicts of interest** No potential conflicts of interest were disclosed.

## References

1. Tolosa E, Wenning G, Poewe W. The diagnosis of Parkinson's disease. *Lancet Neurol*. 2006;5(1):75–86.
2. Marsden CD. Parkinson's disease. *Lancet*. 1990;335(8695):948–52.
3. Wilson JM, Levey AI, Rajput A, Ang L, Guttman M, Shannak K, et al. Differential changes in neurochemical markers of striatal dopamine nerve terminals in idiopathic Parkinson's disease. *Neurology*. 1996;47(3):718–26.
4. Brooks DJ. Molecular imaging of dopamine transporters. *Ageing Res Rev*. 2016;30:114–21.
5. Berti V, Pupi A, Mosconi L. PET/CT in diagnosis of movement disorders. *Ann N Y Acad Sci*. 2011;1228(1):93–108.
6. Hwang WJ, Yao WJ, Wey SP, Ting G. Reproducibility of  $^{99m}\text{Tc}$ -TRODAT-1 SPECT measurement of dopamine transporters in Parkinson's disease. *J Nucl Med*. 2004;45(2):207–13.
7. Kung MP, Stevenson DA, Plossl K, Meegalla SK, Beckwith A, Essman WD, et al. [ $^{99m}\text{Tc}$ ]TRODAT-1: a novel technetium-99m complex as a dopamine transporter imaging agent. *Eur J Nucl Med*. 1997;24(4):372–80.
8. Meegalla S, Plossl K, Kung MP, Chumpradit S, Stevenson DA, Frederick D, et al. Tc-99m-labeled tropanes as dopamine transporter imaging agents. *Bioconjug Chem*. 1996;7(4):421–9.
9. Kung HF, Kim HJ, Kung MP, Meegalla SK, Plossl K, Lee HK. Imaging of dopamine transporters in humans with technetium-99m TRODAT-1. *Eur J Nucl Med*. 1996;23(11):1527–30.
10. Chen YK, Liu RS, Huang WS, Wey SP, Ting G, Liu JC, et al. The role of dopamine transporter imaging agent [ $^{99m}\text{Tc}$ ]TRODAT-1 in hemi-parkinsonism rat brain. *Nucl Med Biol*. 2001;28(8):923–8.
11. Fallahi B, Esmaeili A, Beiki D, Oveisgharan S, Noorollahi-Moghaddam H, Erfani M, et al. Evaluation of ( $^{99m}\text{Tc}$ -TRODAT-1 SPECT in the diagnosis of Parkinson's disease versus other progressive movement disorders. *Ann Nucl Med*. 2016;30(2):153–62.
12. Ma KH, Lee JK, Huang SY, Yeh CB, Shen YC, Shen LH, et al. Simultaneous [ $^{99m}\text{Tc}$ ]TRODAT-1 and [ $^{123}\text{I}$ ]ADAM brain SPECT in nonhuman primates. *Mol Imaging Biol*. 2009;11(4):253–62.
13. Huang WS, Lin SZ, Lin JC, Wey SP, Ting G, Liu RS. Evaluation of early-stage Parkinson's disease with  $^{99m}\text{Tc}$ -TRODAT-1 imaging. *J Nucl Med*. 2001;42(9):1303–8.
14. Sasannezhad P, Juibary AG, Sadri K, Sadeghi R, Sabour M, Kakhki VRD, et al. ( $^{99m}\text{Tc}$ -TRODAT-1 SPECT imaging in early and late onset Parkinson's Disease. *Asia Ocean J Nucl Med Biol*. 2017;5(2):114–9.
15. Chou KL, Hurtig HI, Stern MB, Colcher A, Ravina B, Newberg A, et al. Diagnostic accuracy of [ $^{99m}\text{Tc}$ ]TRODAT-1 SPECT imaging in early Parkinson's disease. *Parkinsonism Relat Disord*. 2004;10(6):375–9.
16. Fang P, Wu CY, Liu ZG, Wan WX, Wang TS, Chen SD, et al. The preclinical pharmacologic study of dopamine transporter imaging agent [ $^{99m}\text{Tc}$ ]TRODAT-1. *Nucl Med Biol*. 2000;27(1):69–75.
17. Meegalla SK, Plossl K, Kung MP, Chumpradit S, Stevenson DA, Kushner SA, et al. Synthesis and characterization of technetium-99m-labeled tropanes as dopamine transporter-imaging agents. *J Med Chem*. 1997;40(1):9–17.
18. Kung HF, Kung MP, Wey SP, Lin KJ, Yen TC. Clinical acceptance of a molecular imaging agent: a long march with [ $^{99m}\text{Tc}$ ]TRODAT. *Nucl Med Biol*. 2007;34(7):787–9.
19. Lin CC, Fan YM, Lin GY, Yang FC, Cheng CA, Lu KC, et al.  $^{99m}\text{Tc}$ -TRODAT-1 SPECT as a potential neuroimaging biomarker in patients with restless legs syndrome. *Clin Nucl Med*. 2016;41(1):e14.

20. Tzen KY, Lu CS, Yen TC, Wey SP, Ting G. Differential diagnosis of Parkinson's disease and vascular parkinsonism by (99m)Tc-TRODAT-1. *J Nucl Med.* 2001;42(3):408–13.
21. Chou MC, Lai PH, Li JY. Early white matter injuries associated with dopamine transporter dysfunction in patients with acute CO intoxication: a diffusion kurtosis imaging and Tc-99m TRODAT-1 SPECT study. *Eur Radiol.* 2019;29(3):1375–83.
22. Wang J, Jiang YP, Liu XD, Chen ZP, Yang LQ, Liu CJ, et al. 99mTc-TRODAT-1 SPECT study in early Parkinson's disease and essential tremor. *Acta Neurol Scand.* 2005;112(6):380–5.
23. Ping W, Ping H, Dian-Chao Y, Hong L, Jie-Hua X. The clinical value of Tc-99m TRODAT-1 SPECT for evaluating disease severity in young patients with symptomatic and asymptomatic Wilson disease. *Clin Nucl Med.* 2007;32(11):844–9.
24. Bor-Seng-Shu E, Felicio AC, Braga-Neto P, Batista IR, Paiva WS, de Andrade DC, et al. Dopamine transporter imaging using 99mTc-TRODAT-1 SPECT in Parkinson's disease. *Med Sci Monit.* 2014;20:1413–8.
25. Weng YH, Yen TC, Chen MC, Kao PF, Tzen KY, Chen RS, et al. Sensitivity and specificity of 99mTc-TRODAT-1 SPECT imaging in differentiating patients with idiopathic Parkinson's disease from healthy subjects. *J Nucl Med.* 2004;45(3):393–401.
26. la Fougere C, Krause J, Krause KH, Josef Gildehaus F, Hacker M, Koch W, et al. Value of 99mTc-TRODAT-1 SPECT to predict clinical response to methylphenidate treatment in adults with attention deficit hyperactivity disorder. *Nucl Med Commun.* 2006;27(9):733–7.
27. Kish SJ, Shannak K, Hornykiewicz O. Uneven pattern of dopamine loss in the striatum of patients with idiopathic Parkinson's disease. Pathophysiologic and clinical implications. *N Engl J Med.* 1988;318(14):876–880.
28. Huang WS, Ma KH, Chou YH, Chen CY, Liu RS, Liu JC. 99mTc-TRODAT-1 SPECT in healthy and 6-OHDA lesioned parkinsonian monkeys: comparison with 18F-FDOPA PET. *Nucl Med Commun.* 2003;24(1):77–83.
29. Shyu WC, Lin SZ, Chiang MF, Pang CY, Chen SY, Hsin YL, et al. Early-onset Parkinson's disease in a Chinese population: 99mTc-TRODAT-1 SPECT, Parkin gene analysis and clinical study. *Parkinsonism Relat Disord.* 2005;11(3):173–80.
30. Bao SY, Wu JC, Luo WF, Fang P, Liu ZL, Tang J. Imaging of dopamine transporters with technetium-99m TRODAT-1 and single photon emission computed tomography. *J Neuroimaging.* 2000;10(4):200–3.
31. Mittal BR, Sood A, Shukla J, Vatsa R, Bhusari P, Shree R, et al. 99mTc-TRODAT-1 SPECT/CT imaging as a complementary biomarker in the diagnosis of parkinsonian syndromes. *Nucl Med Commun.* 2018;39(4):312–8.
32. Patel A, Simon S, Elangoven IM, Amalchandran J, Amalchandran SJ, Jain ST. Dopamine Transporter maging with Tc-99m TRODAT-1 SPECT in Parkinson's isease and its orrelation with lincal isease everity. *Asia Ocean J Nucl Med Biol* 2019;7(1):22–28
33. Shinto AS, Antony J, Kamaleshwaran K, Vijayan K, Selvan A, Korde A, et al. Correlative 99mTc-labeled tropene derivative single photon emission computer tomography and clinical assessment in the staging of Parkinson disease. *World J Nucl Med.* 2014;13(3):178–83.
34. Wooten GF. Are men at greater risk for Parkinson's disease than women? *J Neurol Neurosurg Psychiatry.* 2004;75(4):637–9.
35. Taylor KS, Cook JA, Counsell CE. Heterogeneity in male to female risk for Parkinson's disease. *J Neurol Neurosurg Psychiatry.* 2007;78(8):905–6.
36. Moisan F, Kab S, Mohamed F, Canonico M, Le Guern M, Quintin C, et al. Parkinson disease male-to-female ratios increase with age: French nationwide study and meta-analysis. *J Neurol Neurosurg Psychiatry.* 2016;87(9):952–7.
37. Picillo M, Nicoletti A, Fetoni V, Garavaglia B, Barone P, Pellecchia MT. The relevance of gender in Parkinson's disease: a review. *J Neurol.* 2017;264(8):1583–607.
38. Tanner CM, Goldman SM. Epidemiology of Parkinson's disease. *Neurol Clin.* 1996;14(2):317–35.
39. Inestrosa NC, Marzolo MP, Bonnefont AB. Cellular and molecular basis of estrogen's neuroprotection. Potential relevance for Alzheimer's disease. *Mol Neurobiol* 1998;17 (1–3):73–86
40. Pankratz N, Nichols WC, Uniacke SK, Halter C, Rudolph A, Shults C, et al. Genome screen to identify susceptibility genes for Parkinson disease in a sample without parkin mutations. *Am J Hum Genet.* 2002;71(1):124–35.
41. Oostra RJ, Kemp S, Bolhuis PA, Bleeker-Wagemakers EM. No evidence for 'skewed' inactivation of the X-chromosome as cause of Leber's hereditary optic neuropathy in female carriers. *Hum Genet.* 1996;97(4):500–5.
42. Mozley PD, Stubbs JB, Plossl K, Dresel SH, Barraclough ED, Alavi A, et al. Biodistribution and dosimetry of TRODAT-1: a technetium-99m tropene for imaging dopamine transporters. *J Nucl Med.* 1998;39(12):2069–76.

**Publisher's Note** Springer Nature remains neutral with regard to jurisdictional claims in published maps and institutional affiliations.